



KEMENTERIAN PENDIDIKAN DAN KEBUDAYAAN
UNIVERSITAS HASANUDDIN FAKULTAS KEDOKTERAN
KOMITE ETIK PENELITIAN KESEHATAN
RSPTN UNIVERSITAS HASANUDDIN



RSUP Dr. WAHIDIN SUDIROHUSODO MAKASSAR
Sekretariat : Lantai 2 Gedung Laboratorium Terpadu
JL.PERINTIS KEMERDEKAAN KAMPUS TAMALANREA KM.10 MAKASSAR 90245.



Contact Person: dr. Agussalim Bukhari.,MMed.PhD, SpGK TELP. 081241850858, 0411 5780103, Fax : 0411-581431

REKOMENDASI PERSETUJUAN ETIK

Nomor : 1142/UN4.6.4.5.31/ PP36/ 2019

Tanggal: 29 Nopember 2019

Dengan ini Menyatakan bahwa Protokol dan Dokumen yang Berhubungan Dengan Protokol berikut ini telah mendapatkan Persetujuan Etik :

No Protokol	UH19090685	No Sponsor Protokol	
Peneliti Utama	dr. Muhlis, SpKK, M.Kes	Sponsor	
Judul Peneliti	Efek Serum Autologous Terhadap Perubahan Manifestasi Klinik Penderita Akne Vulgaris		
No Versi Protokol	2	Tanggal Versi	13 Nopember 2019
No Versi PSP	2	Tanggal Versi	13 Nopember 2019
Tempat Penelitian	RSUP Dr Wahidin Sudirohusodo, RS Universitas Hasanuddin, RS Jejaring, BP Kulit dan Kelamin Veteran Makassar		
Jenis Review	<input type="checkbox"/> Exempted <input checked="" type="checkbox"/> Expedited <input type="checkbox"/> Fullboard Tanggal	Masa Berlaku 29 Nopember 2019 sampai 29 Nopember 2020	Frekuensi review lanjutan
Ketua Komisi Etik Penelitian Kesehatan FKUH	Nama Prof.Dr.dr. Suryani As'ad, M.Sc.,Sp.GK (K)	Tanda tangan 	
Sekretaris Komisi Etik Penelitian Kesehatan FKUH	Nama dr. Agussalim Bukhari, M.Med.,Ph.D.,Sp.GK (K)	Tanda tangan 	

Kewajiban Peneliti Utama:

- Menyerahkan Amandemen Protokol untuk persetujuan sebelum di implementasikan
- Menyerahkan Laporan SAE ke Komisi Etik dalam 24 Jam dan dilengkapi dalam 7 hari dan Laporan SUSAR dalam 72 Jam setelah Peneliti Utama menerima laporan
- Menyerahkan Laporan Kemajuan (progress report) setiap 6 bulan untuk penelitian resiko tinggi dan setiap setahun untuk penelitian resiko rendah
- Menyerahkan laporan akhir setelah Penelitian berakhir
- Melaporkan penyimpangan dari prokol yang disetujui (protocol deviation / violation)
- Mematuhi semua peraturan yang ditentukan



The Effectiveness of Autologous Serum and Single-dose Oral Doxycycline in the Treatment of Acne Vulgaris: A Pilot Clinical Trial

Muhammad Nasrum Massi^{1*}, Muhlis Yunus², Anis Irawan Anwar², Khairuddin Djawad², Siswanto Wahab², Rahmawati Minhajat³, Uleng Bahrin⁴, Ilhamjaya Patellongi⁵, Gemini Alam⁶, Ni Nyoman Sri Budayanti⁷

¹Department of Clinical Microbiology, Faculty of Medicine, Hasanuddin University, Makassar, Indonesia; ²Department of Dermatology and Venereology, Faculty of Medicine, Hasanuddin University, Makassar, Indonesia; ³Department of Internal Medicine, Faculty of Medicine, Hasanuddin University, Makassar, Indonesia; ⁴Department of Clinical Pathology, Faculty of Medicine, Hasanuddin University, Makassar, Indonesia; ⁵Department of Physiology, Faculty of Medicine, Hasanuddin University, Makassar, Indonesia; ⁶Department of Pharmacy, Faculty of Pharmacy, Hasanuddin University, Makassar, Indonesia; ⁷Department of Clinical Microbiology, Faculty of Medicine, Udayana University, Denpasar, Bali, Indonesia

Abstract

BACKGROUND: Acne vulgaris is a chronic inflammatory disease that occurs with various factors, both intrinsic and extrinsic. Treatment of choice can vary from topical, systemic or a combination of both depending on the degree of severity. Recently, treatment using products from human blood has been widely studied, including in the field of dermatology as it has a unique composition.

AIM: The objective of the study was to assess the effectiveness of autologous serum and single-dose oral doxycycline in the treatment of acne vulgaris

METHODS: This clinical trial compared two groups which received autologous serum only and autologous serum combined with single dose of oral 200 mg doxycycline, respectively. Photographic pictures and number of lesions (blackheads, papules, and pustules) were compared before and after application using Wilcoxon test.

RESULTS: A total of 20 participants participated in this study. Both treatment groups showed significant decrease in lesion count ($p < 0.01$). However, the group which received autologous serum and single dose of oral doxycycline showed superior improvement of inflammatory acne lesions.

CONCLUSION: Autologous serum and single dose of oral doxycycline was superior to autologous serum only in the treatment acne lesions.

Edited by: Ksenija Bogoeva-Kostovska
Citation: Massi MN, Yunus M, Anwar AI, Djawad K, Wahab S, Minhajat R, Bahrin U, Patellongi I, Alam G, Budayanti NNS. The Effectiveness of Autologous Serum and Single-dose Oral Doxycycline in the Treatment of Acne Vulgaris: A Pilot Clinical Trial. Open Access Maced J Med Sci. 2021 Nov 28; 9(B):1602-1606. https://doi.org/10.3889/oamjms.2021.6874
Keywords: Acne vulgaris; Doxycycline; Autologous serum
***Correspondence:** Muhammad Nasrum Massi, Department of Clinical Microbiology, Faculty of Medicine, Hasanuddin University, Makassar, Indonesia. E-mail: nasrumm2000@yahoo.com
Received: 19-Jul-2021
Revised: 10-Sep-2021
Accepted: 18-Nov-2021
Copyright: © 2021 Muhammad Nasrum Massi, Muhlis Yunus, Anis Irawan Anwar, Khairuddin Djawad, Siswanto Wahab, Rahmawati Minhajat, Uleng Bahrin, Ilhamjaya Patellongi, Gemini Alam, Ni Nyoman Sri Budayanti
Funding: This research did not receive any financial support
Competing Interests: The authors have declared that no competing interests exist
Open Access: This is an open-access article distributed under the terms of the Creative Commons Attribution-NonCommercial 4.0 International License (CC BY-NC 4.0)

Introduction

Acne vulgaris is a chronic inflammatory disease that occurs due to a variety of both intrinsic and extrinsic factors. Treatments vary from topical, systemic, or a combination of both depending on the degree of severity. Acne vulgaris is a disease of the pilosebaceous unit, the sebaceous glands are found throughout the human skin and has greater concentration on the face and scalp but absent on the palms of the hands and soles of the feet. These glands store sebum in the hair and carry it to the surface along the hair shaft [1]. Sebum provides lubrication and hydration and composed of triglycerides, free fatty acids, and aliphatic hydrocarbons [2]. Acne arises from the interaction of four major pathogenic processes: Hyperproliferation of sebaceous glands; hyperproliferation of keratinocytes; colonization of *Propionibacterium acnes*; and the presence of

inflammation. These pathogenic factors influence each other and should not be approached individually. Although the interaction of pathogenic factors is known to cause acne, certain trigger factors can worsen or cause acne to appear. Examples of these trigger factors are premenstrual and cosmetic use [3]. Treatment can vary from topical, systemic or a combination of both depending on the degree of severity. Recently, treatment using products from human blood has been widely researched, including in the field of dermatology because of its unique composition [4].

Therapeutic modalities for the treatment of acne vulgaris include topical and systemic therapy. Topical therapy includes the use of antibiotics and Vitamin A derivatives while options of systemic therapy are oral antibiotics, Vitamin A derivatives and hormonal drugs. Based on the pathomechanism of acne vulgaris, the current therapeutic modality can be given through topical, systemic, or a combination of both [5]. However,

in certain cases, such as hypersensitivity reactions, these drug preparations cannot be administered. These conditions include allergies and unwanted side effects [6]. This study aims to assess the effect of autologous serum derived after single-dose doxycycline administration and doxycycline in autologous serum in the treatment of acne vulgaris.

Methods

This was a pre- and post-treatment clinical trial in two treatment groups with each group consisted of ten people with acne vulgaris. All eligible subjects were randomly allocated into two groups: Those receiving autologous serum and those receiving oral doxycycline, respectively. Subjects were equally divided into two groups with one group receiving autologous serum and another receiving a combination of autologous serum and a single dose of oral 200 mg doxycycline; both treatments were applied for 28 days. Males and females aged 15–35 years old with no recent or current acne therapy and not pregnant (for women) were eligible to participate in this study. This study had obtained approval from the local ethical board committee.

The autologous serum in the first group was made by drawing 50 cc blood from the cubital vein which was then inserted into a tube without a coagulant. The tube was then centrifuged for 10–15 min at a speed of 3000 rpm which separated the clear blood plasma from the blood. Meanwhile, the other group was given a single dose of oral 200 mg doxycycline and, after 2 h, had 50 cc of venous blood drawn followed by the same centrifugation process. The serum obtained from the centrifuge process was put into a small bottle containing 1–2 cc for one application. The serum was stored in a refrigerator at 0°C and applied every night to areas of the face with acne lesions for 28 days. Before the serum was applied, patients were asked to wash their face without using soap or other cosmetic products. To see the changes that occur, photographic pictures and number of lesions (blackheads, papules, and pustules) were compared before and after application.

Results

A total of 20 subjects participated in this study. All participants were female and the average age in each group was 22.4 years and 24.6 years ($p > 0.05$).

In the autologous serum only group, an improvement of acne lesions was seen after 28 days (Figure 1). A decrease in lesions by 11.7%, papules 15%, and pustules 15.4% was seen after the

administration (Table 1). Wilcoxon test showed that the number of blackheads, papules, and pustules decreased significantly after 28 days of treatment ($p < 0.05$).

Table 1: Post-treatment result of the autologous serum only group

Variable	D1– D28	
	Median	p-value*
Decrease in number of blackheads (%)	60.2 (11.7)	<0.001
Decrease in number of papules (%)	54.4 (15.0)	<0.001
Decrease in number of pustules (%)	78.9 (15.4)	<0.001

*Significant if $p < 0.05$ (Wilcoxon test).

In the autologous serum and doxycycline group, an improvement of blackhead lesions was seen after 28 days (Figure 2). A decrease in lesions by 18.8%, papules 26.6%, and pustules 56.0% was seen after the administration (Table 2). Wilcoxon test showed that the number of blackheads, papules, and pustules decreased significantly after 28 days of treatment ($p < 0.05$).

Discussion

In patients with acne vulgaris, hyperproliferation of keratinocytes that occur results in the accumulation of abnormal corneocyte desquamation on the sebaceous follicles along with lipids and monofilaments, resulting in the formation of blackheads. *P. acne* is a Gram-negative anaerobic pathogen colonizing the sebaceous follicles. In accordance to the pharmacokinetic properties of doxycycline, blood sampling is taken every 2 h after the administration of oral doxycycline 200 mg as this drug reaches peak concentration in 2 h after administration. Doxycycline is one of the most effective oral antibiotics for inflammatory acne and therefore is used to effectively inhibit the growth of *P. acne* [7]. The use of oral antibiotics is generally indicated for moderate to severe inflammatory acne, or those who are resistant to previous topical therapy. Oral antibiotics such as macrolides, tetracyclines (doxycycline, minocycline, and lymecycline) are often used. These antibiotics are agents that inhibit the growth of *P. acne* in addition to their anti-inflammatory property. Tetracyclines are used frequently because due to the low-cost and high efficacy. Doxycycline and minocycline are preferred because of their low gastrointestinal irritation effect, solubility in fats, and better penetration of the pilosebaceous follicles. In addition, the resistance rate of *P. acne* to this class was less frequently reported compared to macrolides.

Some unique ingredients of serum include growth factor, platelet-rich plasma (PRP), Vitamin A, and many more. As we know that topical acne vulgaris treatment uses topical Vitamin A derivatives (tretinoin) which works by its anti-inflammatory, suppression of sebum production, and increases skin turnover [8]. In this study, the measurement of serum Vitamin A content

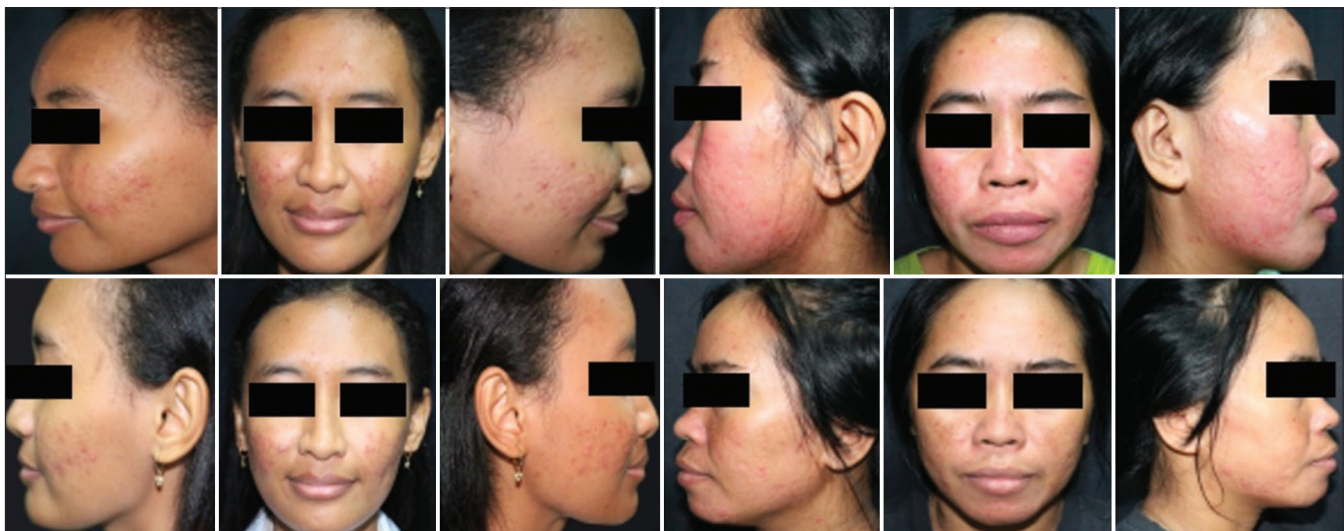

Figure 1: Clinical improvement after 28 days of the autologous serum only group

Table 2: Post-treatment result of the autologous serum and single 200 mg doxycycline

Variable	D1-D28	
	Median	p-value*
Decrease in number of blackheads (%)	98 (18.8)	<0.001
Decrease in number of papules (%)	37 (26.6)	<0.001
Decrease in number of pustules (%)	18 (56.0)	<0.001

*Significant if p < 0.05 (Wilcoxon test).

was done using Enzyme-Linked Immunosorbent Assay test.

Kinda *et al.* explain that Vitamin A (All-trans retinoic acid [ATRA]) and Vitamin D (1,25D3) share the retinoid X receptor as a common receptor that encodes and functions to inhibit Th17. ATRA and 1,25D3 are generally used for therapy by dermatologists because they have the ability to modulate the immune response [9].

In this study, menstrual estradiol levels (follicular phase) were obtained in levels ranging from 20.8 to 200.5 pg/mL. The concentration of estradiol levels is lowest during the menstrual phase with serum concentrations around 40–200 pg/mL. Meanwhile, the level of estradiol during preovulation was around 250–500 pg/mL, so it was concluded that the estrogen levels in the menstrual phase were lower than that of the preovulatory phase. Low estrogen levels are associated with the severity of acne. Androgen hormones increase the production of sebum, so that the sebum levels in patients with acne vulgaris are higher than in normal people [10]. There is a relationship between sebum excretion and the severity of acne vulgaris because the sebum levels in patients with severe acne vulgaris are found to be higher in levels. Estradiol can inhibit sebum production to reduce sebum levels. The use of

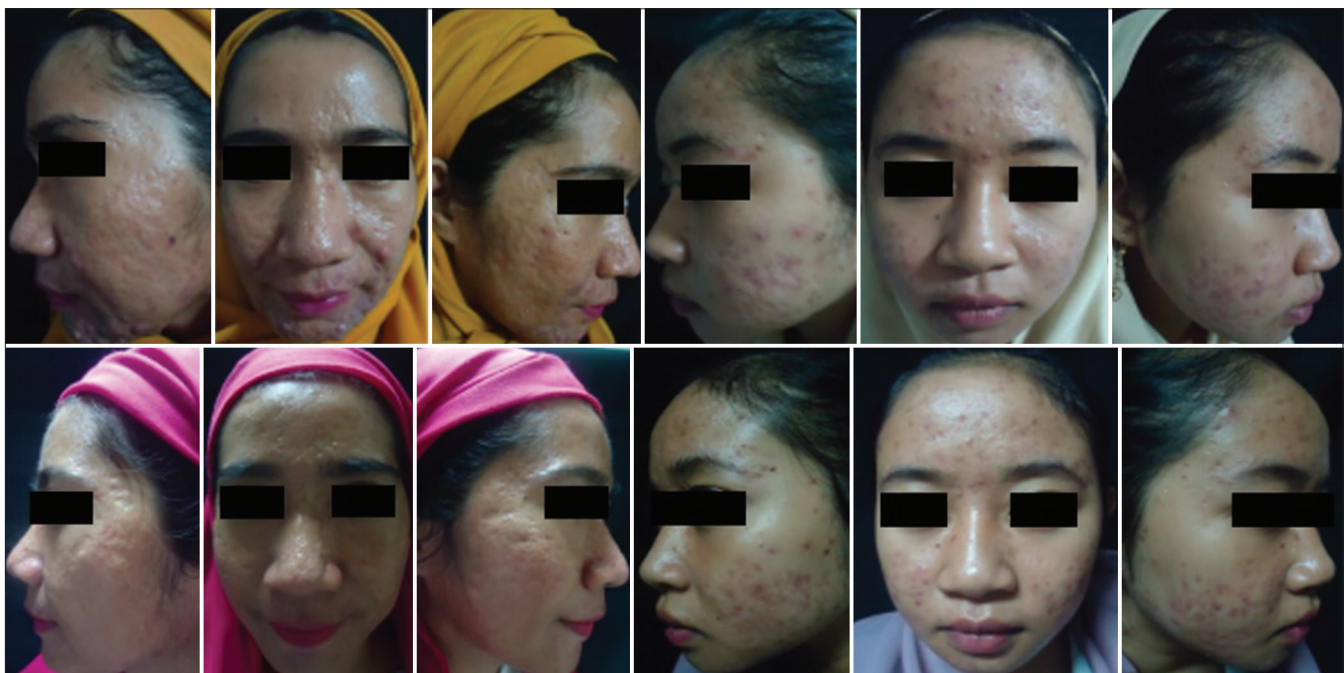

Figure 2: Clinical improvement after 28 days of the autologous serum and doxycycline group

oral contraceptives for the treatment of acne vulgaris contains estradiol [11].

PRP works through alpha-granule degranulation in platelets containing growth factors. It is ideal to collect the PRP blood in a tube containing sodium citrate as an anticoagulant to keep growth factor active. Biologically active cellular components such as growth factors are preserved, when the platelets are held in an inactive state so that premature degranulation does not occur; therefore, the cellular components are held in a container that can protect the platelets. After platelet activation, the granules then fuse into the cell membrane by a degranulation process, activating growth factors, which bind to target cell transmembrane receptors, such as mesenchymal stem cells, fibroblasts, endothelial cells, and epidermal cells. This binding activates intracellular signaling proteins that express gene sequences resulting in cell proliferation, collagen synthesis, cell extracellular formation, and many other pathways to promote healing and repair processes. Platelets are damaged with degraded cellular components or are unable to induce this response [12], [13].

Based on this theory, PRP can be used for skin rejuvenation because it can activate growth factors that result in cell proliferation and stimulate collagen synthesis which can lead to healing and repair processes. In addition, PRP is reported to be associated with collagen expression, hyaluronic acid production, and fibroblast proliferation which is thought to be mediated by insulin-like growth factor, epidermal growth factor which binds to the outer surface of the fibroblast cell membrane activates signal proteins to realize extracellular matrix synthesis and collagen repackaging. Transforming Growth Factor b1 and platelet-derived growth factor are able to increase hyaluronic acid synthesis by increasing regulation of hyaluronic synthase expression. Hyaluronic acid can attract water into the space between cells and retain intracellular water so to maintain skin elasticity [13], [14], [15].

The improvement in acne lesions in this study was thought to be due to the involvement of growth factors, PRP, Vitamin A, and estradiol. Vitamin A works as an anti-inflammatory reduces sebum production, and increases skin turnover, estradiol works to inhibit androgens so that it can control reducing sebum production, growth factor works as an anti-inflammatory. Based on these contents, it is assumed that in the autologous serum that works together according to the pathogenesis of acne vulgaris.

Although the decrease in lesion number was more significant in the combination group, a head-to-head comparison was unable to be done due to the limited number of subjects in each group. Future studies with larger number of participants should be conducted to confirm this result.

Conclusion

Autologous serum contains many components including growth factors, PRP, Vitamin A, and estradiol which work synergistically to inhibit the pathomechanism of acne vulgaris. Addition of doxycycline 200 mg orally as a single dose functions as an anti-inflammatory agent and was effective in improving acne lesions.

References

- Engler D. Acne. *S Afr Pharm J*. 2016;83(10):27-34.
- Fox L, Csongradi C, Aucamp M, du Plessis J, Gerber M. Treatment modalities for acne. *Molecules*. 2016;21(8):1063. <http://doi.org/10.3390/molecules21081063> PMID:27529209
- Bhat YJ, Latief I, Hassan I. Update on etiopathogenesis and treatment of Acne. *Indian J Dermatol Venereol Leprol*. 2017;83(3):298-306. <http://doi.org/10.4103/0378-6323.199581> PMID:28195079
- Thielitz A, Krautheim A, Gollnick H. Update in retinoid therapy of acne. *Dermatol Ther*. 2006;19(5):272-9. <http://doi.org/10.1111/j.1529-8019.2006.00084.x> PMID:17014482
- Lynn DD, Umari T, Dunnick CA, Dellavalle RP. The epidemiology of acne vulgaris in late adolescence. *Adolesc Health Med Ther*. 2016;7:13-25. <http://doi.org/10.2147/AHMT.S55832> PMID:26955297
- Pugashetti R, Shinkai K. Treatment of acne vulgaris in pregnant patients. *Dermatol Ther*. 2013;26(4):302-11. <http://doi.org/10.1007/s40265-013-0060-0> PMID:23657872
- Tan AU, Schlosser BJ, Paller AS. A review of diagnosis and treatment of acne in adult female patients. *Int J Womens Dermatol*. 2018;4(2):56-71. <http://doi.org/10.1016/j.ijwd.2017.10.006> PMID:29872679
- Langer C, Mahajan V. Platelet-rich plasma in dermatology. *J K Sci*. 2014;16(4):147-50.
- Kelhälä HL, Palatsi R, Fyhrquist N, Lehtimäki S, Väyrynen JP, Kallioinen M, et al. IL-17/Th17 pathway is activated in acne lesions. *PLoS One*. 2014;9(8):e105238. <http://doi.org/10.1371/journal.pone.0105238> PMID:25153527
- Shaw JC. Acne: Effect of hormones on pathogenesis and management. *Am J Clin Dermatol*. 2002;3(8):571-8. <http://doi.org/10.2165/00128071-200203080-00007> PMID:12358558
- Sexton S. Acne vulgaris: Treatment guidelines from the AAD. *J Am Acad Dermatol*. 2016;74(5):945-73.
- Kumar S, Mahajan BB, Kaur S, Singh A. Autologous therapies in dermatology. *J Clin Aesthet Dermatol*. 2014;7(12):38-45. PMID:25584137
- Du R, Lei T. Effects of autologous platelet-rich plasma injections on facial skin rejuvenation. *Exp Ther Med*. 2020;19(4):3024-30. <http://doi.org/10.3892/etm.2020.8531>

-
- PMid:32256789
14. Draelos ZD, Rheins LA, Wootten S, Kellar RS, Diller RB. Pilot study: Autologous platelet-rich plasma used in a topical cream for facial rejuvenation. *J Cosmet Dermatol.* 2019;18(5):1348-52. <http://doi.org/10.1111/jocd.13088>
PMid:31350798
15. Amable PR, Carias RB, Teixeira MV, da Cruz Pacheco I, Corrêa do Amaral RJ, Granjeiro JM, *et al.* Platelet-rich plasma preparation for regenerative medicine: optimization and quantification of cytokines and growth factors. *Stem Cell Res Ther.* 2013;4(3):67. <http://doi.org/10.1186/scrt218>
PMid:23759113